



THE BARN
EQUINE
SURGERY

Laminitis Cushing's and EMS

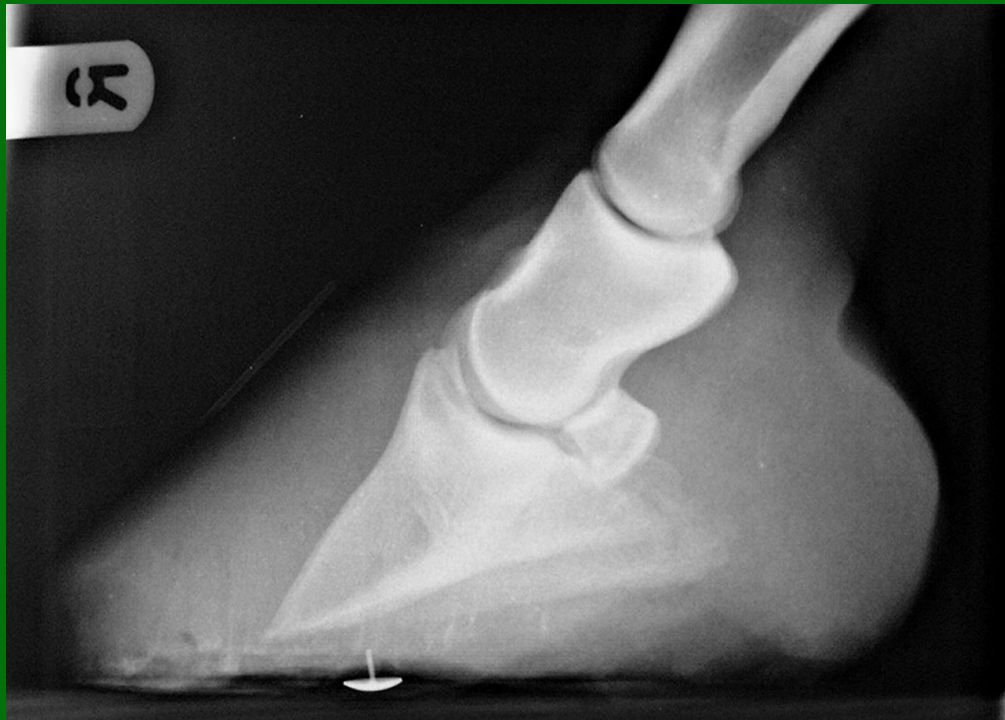Martin Peaty
BVSc CertEP
CertES(Orth) MRCVS

www.barnequine.co.uk



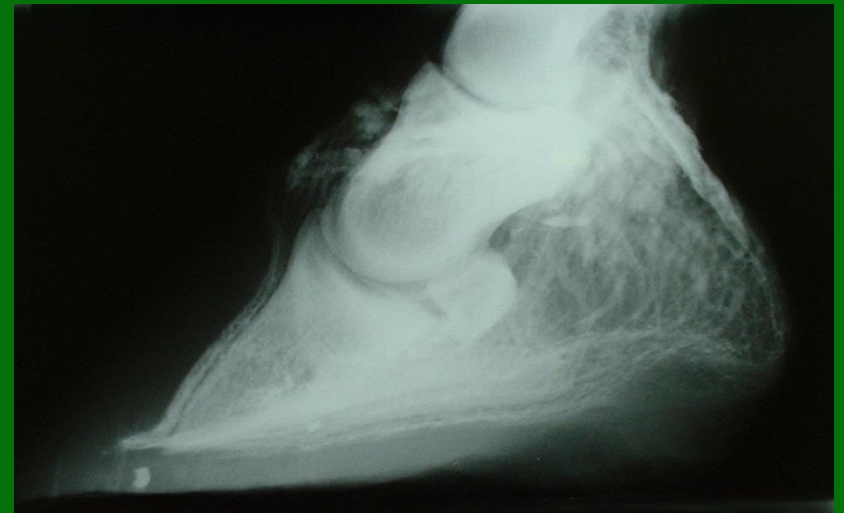LAMINITIS

- Common
- Very painful
- Sometimes fatal
- Permanently deforming



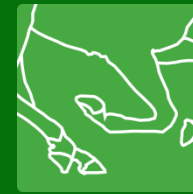Traditional Treatment

- Off grass and diet
- Painkillers 'bute'
- ACP dilates blood vessels and sedates. EBM.
- Support pedal bone - deep bed / frog supports
- X-ray for trimming and
- Heart bar shoes



Cushing's Disease Signs

- Usually 15 years or older
- Laminitis
- Hirsutism
- Body fat redistribution
- Polydipsia /polyuria
- Immunosuppression
- Sweating
- Cataracts

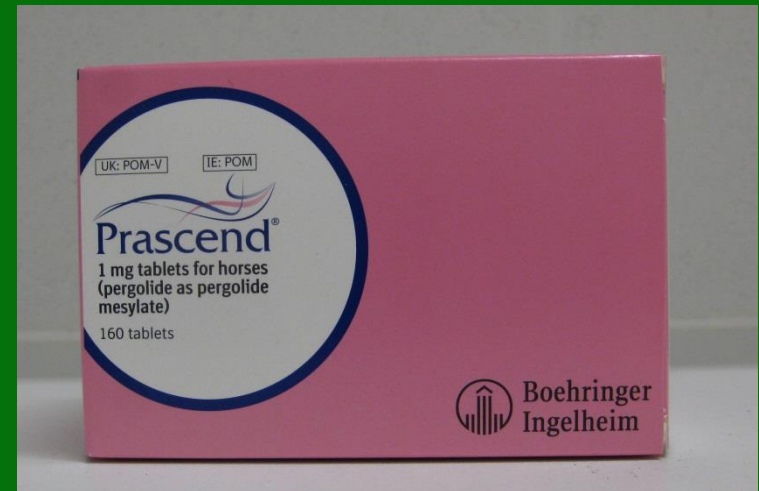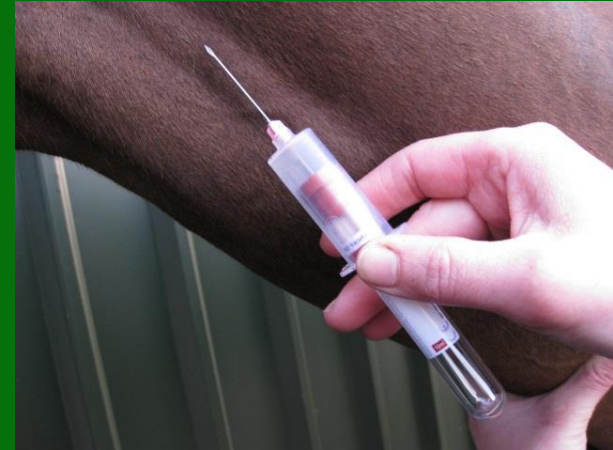


THE BARN
EQUINE
SURGERY

Cushing's Disease

Cause, Diagnosis and Treatment

- Cushing's=PPID Pituitary Pars Intermedia Dysfunction
- Decreased dopamine from hypothalamus
- Increased ACTH- Blood Sample
- Increased cortisol
- Pergolide = Prascend increases dopamine



www.barnequine.co.uk

Equine Metabolic Syndrome

EMS

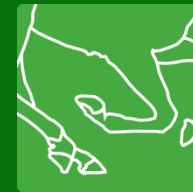

- Caused by Obesity
- Similar type 2 diabetes in people
- Genetic disposition ponies esp Shetlands and donkeys
- Commonest cause of laminitis
- Blood sample after overnight fast
- Glucose tolerance test
- Treated by dieting, exercise and drug (metformin)



Exercise





SCORING condition

Adapted from Carroll and Huntington (1988, EVJ).

Dodson & Horrell Ltd, Ringstead, Kettering, Northants, NN14 4BX
Tel: 01933 624221 Fax: 01933 625461 Website: www.dodsonandhorrell.com

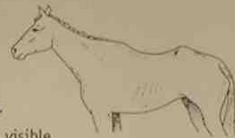zero

VERY POOR

Neck - Marked 'ewe' neck, narrow and slack at base.

Back and Ribs - Skin tight over the ribs, ribs very visible. Spinous processes sharp and easily seen.

Pelvis - Angular pelvis, skin tight, very sunken rump. Deep cavity under tail and either side of croup.



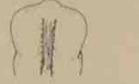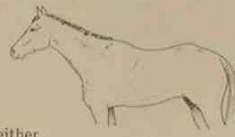one

POOR

Neck - 'Ewe' neck, narrow and slack at base.

Back and Ribs - Ribs easily visible, skin sunken either side of backbone. Spinous processes well defined.

Pelvis - Rump sunken but skin supple, pelvis and croup well defined, cavity under tail.



two

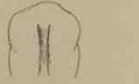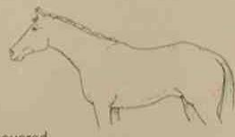MODERATE

A fit racehorse should be carrying this amount of fat.

Neck - Narrow but firm.

Back and Ribs - Ribs just visible, backbone well covered. Spinous processes felt.

Pelvis - Rump flat either side of backbone, croup well defined, some fat, slight cavity under tail.



three

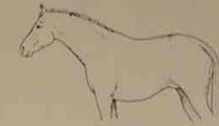GOOD

Most leisure horses will carry this level of fat

Neck - No crest (except stallions), firm neck.

Back and Ribs - Ribs just covered, easily felt. No gutter along back, Spinous processes felt.

Pelvis - Covered by fat and rounded, no gutter, pelvis easily felt.



four

FAT

Neck - Slight crest, wide and firm.

Back and Ribs - Ribs well covered. Gutter along back bone.

Pelvis - Gutter to root of tail. Pelvis covered but soft fat, felt only with firm pressure.



five

VERY FAT

Neck - Marked crest, very wide and firm, folds of fat.

Back and Ribs - Ribs buried cannot feel. Deep gutter, back broad and flat.

Pelvis - Deep gutter to root of tail, skin distended, pelvis buried, cannot feel.



tips

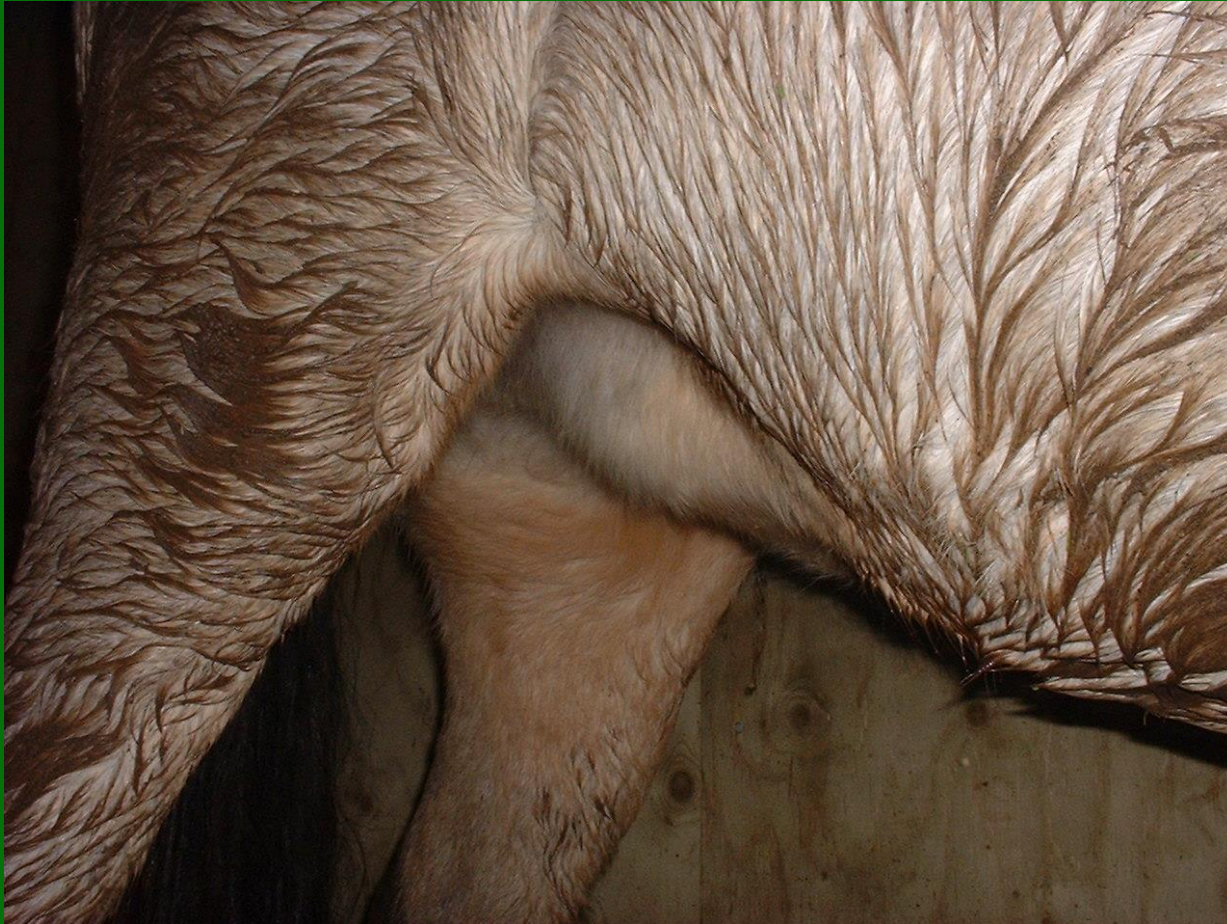- 1 You are scoring for fat cover only.
- 2 Horses store fat on their necks, over their shoulders, over their backbone and ribs and on their rumps, NOT on their underbellies.
- 3 Divide the horse into 3 areas and feel for fat cover.
- 4 Give each area a score and then note the average score.
- 5 Condition score regularly.

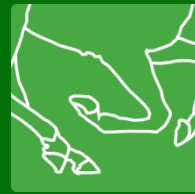

THE BARN
EQUINE
SURGERY

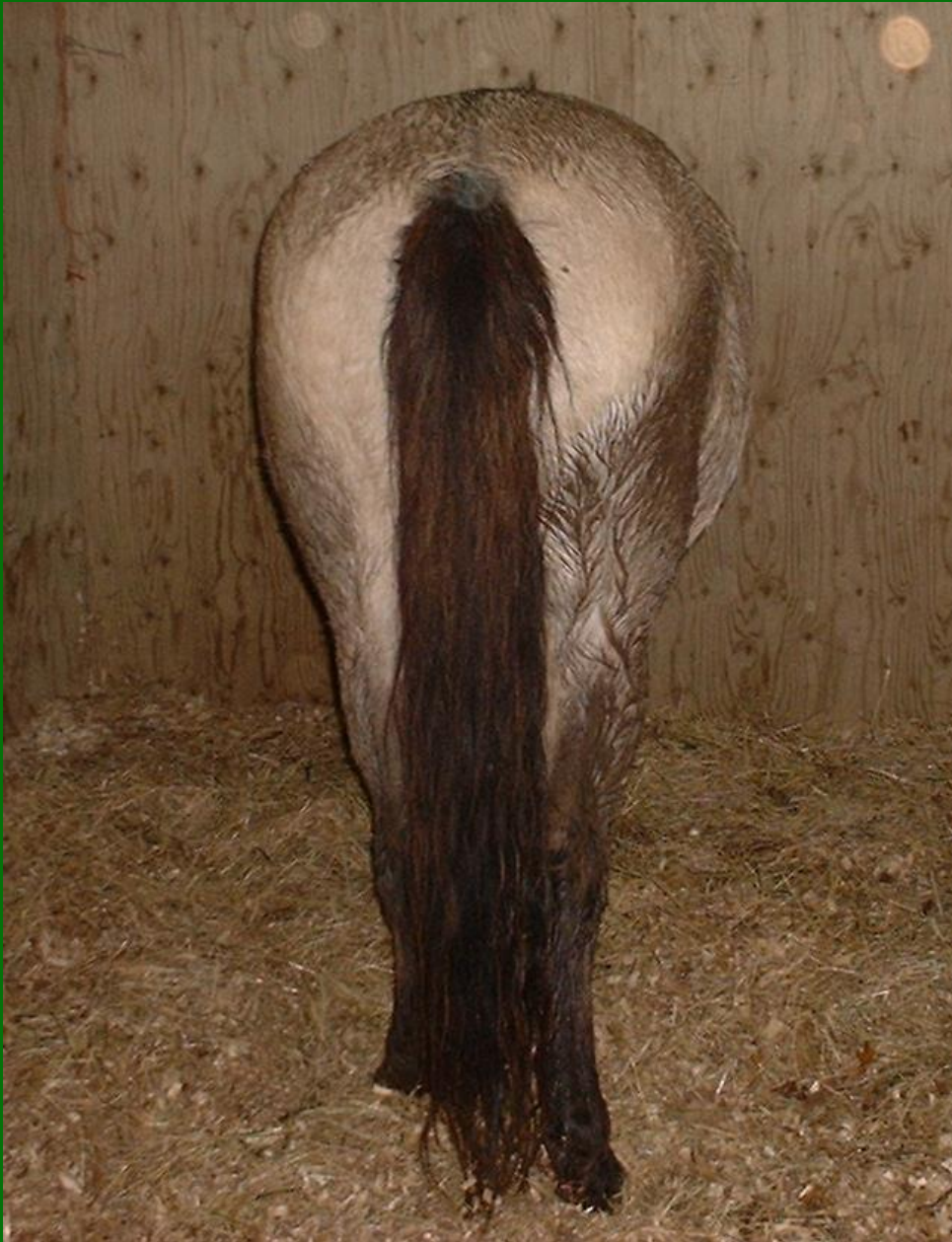

www.barnequine.co.uk





THE BARN
EQUINE
SURGERY



www.barnequine.co.uk



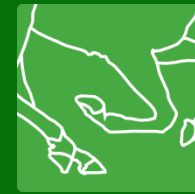THE BARN
EQUINE
SURGERY



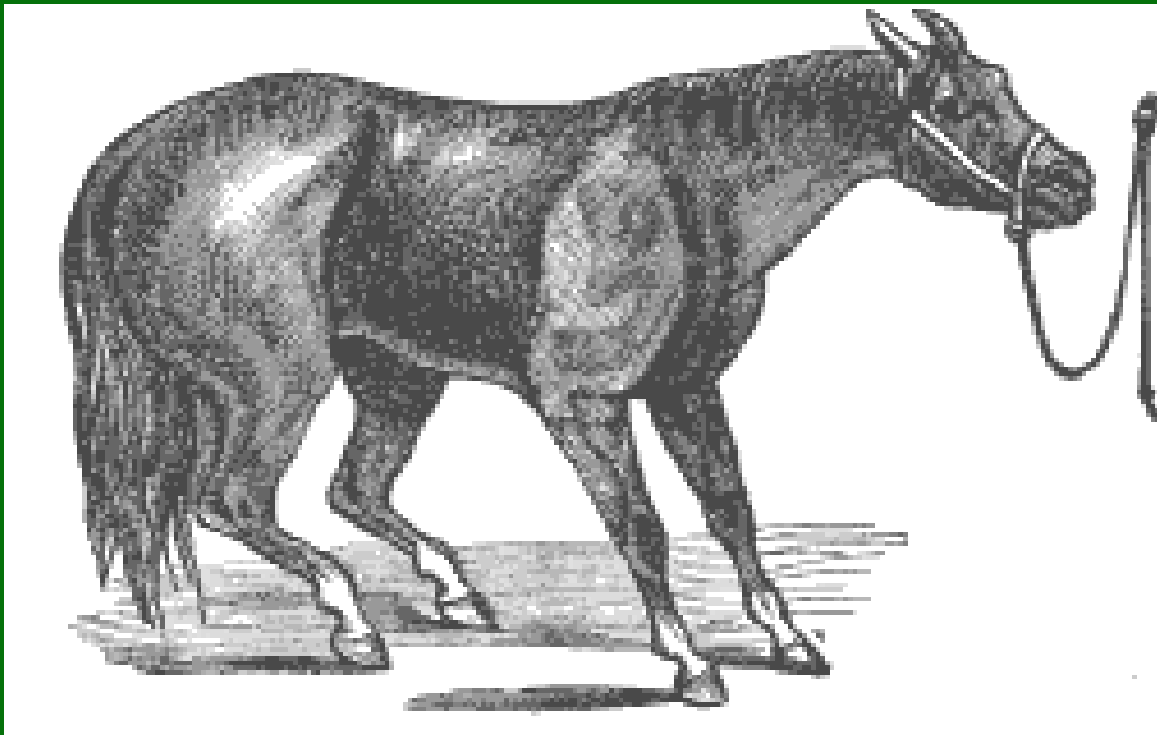
www.barnequine.co.uk

How to Diet

- Limit forage
- Cut out concentrates
- Provide Vitamins and Minerals



THE BARN
EQUINE
SURGERY





THE BARN
EQUINE
SURGERY



www.barnequine.co.uk





THE BARN
EQUINE
SURGERY



www.barnequine.co.uk



THE BARN
EQUINE
SURGERY



www.barnequine.co.uk



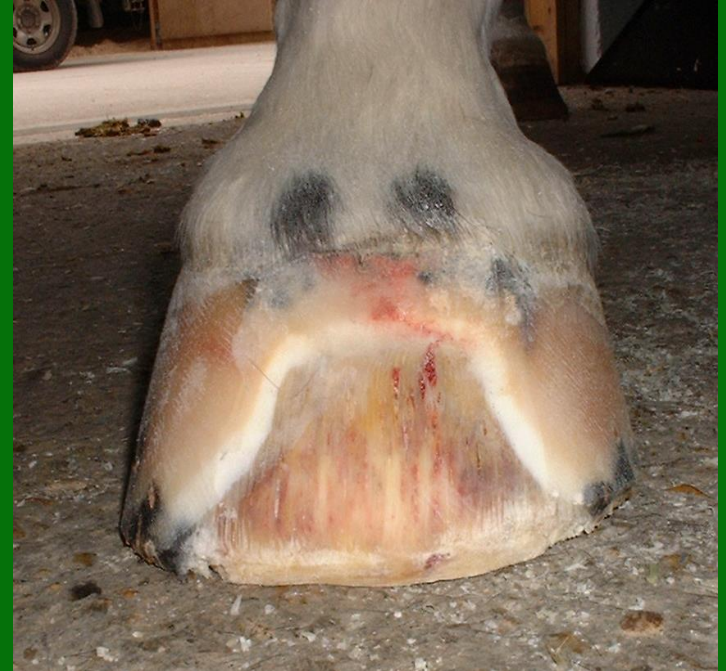THE BARN
EQUINE
SURGERY



www.barnequine.co.uk

Successful Dieting

- Measure heart girth / weight with weigh band
- Record measurement and date so progress and trends can be monitored





THE BARN
EQUINE
SURGERY



www.barnequine.co.uk



Successful Dieting

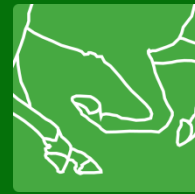- Record weekly to start with
- Set a target (30-60 kg)
- Take 3 months to get there
- Do not starve
- But do be strict!





Other Reasons for Avoiding Obesity

- Lipomas
- Lameness
- Hyperlipaemia
- Allergies



Take Home Message

- Get off grass onto deep bed
- Hormone causes
- Cushing's age and signs
- EMS test if obese
- Traditional T* still important incl painkillers, ACP and frog support
- X-ray and trimming
- X-ray essential for heart bars

What's New?

- Botox
- Metalloproteinase inhibitors

